

Research Article

Radiographic Study of Mental Foramen Type and Position in Bhopal Population using CBCT

Anirban Das, Christopher Vinay Shinde, Gaurav Arya

Department of Oral Medicine & Radiology, People's Dental Academy, People's University, Bhopal (Madhya Pradesh)

ABSTRACT:

Background: This radiographic study was aimed to evaluate the morphology and dimension of mental foramen among Bhopal population. It also investigated the dimorphic variations of mental foramen with respect to gender, type, size and position using CBCT.

Materials & Methods: This study was conducted on 200 individuals of both the genders with the age range of 20 to 60 years who underwent CBCT imaging. The images were then examined for morphology and dimension of mental foramen. The images were evaluated by CS (Carestream) 3D imaging software by two experienced Oral Radiologist.

Results: Mental foramen was found to be large in 70.5%, while only 29.5% showed small size. In the present study 44.5% mental foramen were located in between the first and second premolars and 55.5% at the apex of second premolar's root. The distribution of foramen on the right and left sides in males between the first and second premolars: 44.2% were found on the right side and 55.8% were found on the left side. In the present study majority of the foramen were oval shaped and only 19% were of round shape. At the apex of roots of 2nd premolar, males showed 47.4% at right side and 52.6% at left side while in females, 48.1% were present at right and 51.9% were present at left side.

Conclusion: Mental foramen in each person presents particularities, the anatomic variations, increasing the risks during intervention. So, the clinician should confirm using 3D volumetric radiography during the preoperative phase to organize the patient treatment.

KEYWORDS: Digitalized volumetric tomography, anatomic variations, mental foramen.

Address for correspondence : Dr. Christopher Vinay Shinde, Department of Oral Medicine & Radiology, Peoples Dental Academy, People's University, Bhopal (Madhya Pradesh), India, E-mail: christophershinde@gmail.com

Submitted: 0000 **Accepted:** 0000, **Published:** 0000

INTRODUCTION:

Mental foramen is an anatomical landmark located on the anterolateral surface of the body of the mandible. It marks the termination of the mandibular canal in the mandible, through which the inferior alveolar nerve and vessels pass. It forms an important anatomical landmark in the mandible.^[1] A complete understanding of this structure is essential, as it emerges as a neurovascular bundle, and any direct or indirect damage during surgical procedure would lead to complications.^[2] It is known that there are no absolute

anatomical landmarks for reference, and the foramen cannot be clinically visualized or palpated. The mental foramen differs in size, shape and location which may be related to race, age and gender.^[3] Several imaging modalities have been used to evaluate the morphology and morphometry of mental foramen and anterior loop of mental nerve. Cone beam computed tomography (CBCT) has brought about paradigm shift in diagnostic imaging and has helped overcome the limitations of two-dimensional imaging. CBCT is a volumetric imaging modality which is ideal for capturing anatomic structures with less radiation exposure (0.04 – 0.17

This is an open access journal, and articles are distributed under the terms of the Creative Commons Attribution-Non Commercial ShareALike 4.0 License, which allows others to remix, tweak, and build upon the work non-commercially, as long as appropriate credit is given and the new creations are licensed under the identical terms.

For reprints contact: editor.pjsr@peoplesuniversity.edu.in

How to cite this article: Das A, Shinde CV, Arya G. Radiographic Study of Mental Foramen Type and Position in Bhopal Population using CBCT. PJSR. 2025;18(1):00-00.

Access this article online

Quick Response Code:	Website: www.pjsr.org
	DOI:

mSv), is cost effective and has short acquisition time. All these considerations make CBCT a very promising imaging modality in maxillofacial diagnosis.^[4] This research was designed to determine the morphology and morphometry of mental foramen using CBCT scan.

MATERIALS & METHODS:

This prospective, cross-sectional *in vivo* observational study after approval from the Institutional Ethical Committee recruited 200 patients from the outpatient Department of Oral Medicine and Radiology of People's Dental Academy, Bhopal (M.P.)

The inclusion criteria were as follows:

1. Age group of patients between 20 and 60 years
2. Patients with edentulous areas in the posterior region of the mandible.

The exclusion criteria were as follows:

1. Patients with systemic disease (rheumatoid arthritis, osteomalacia, osteogenesis imperfecta, osteoporosis) which can affect bone integrity
2. Patients suffering from bleeding disorders (hemorrhagic diathesis, drug-induced)
3. Anticoagulation
4. Patients with pathologies in the upper and lower jaws and oral mucous membrane
5. Immunocompromised patients (HIV, immune suppressive medications)
6. Drug abusers, alcohol consumers, and heavy smokers
7. Psychological and mental disorders
8. Noncompliant patients
9. Patients who underwent radiotherapy
10. Patients with habit of bruxism
11. Patients on I.V. bisphosphonates.

METHODOLOGY:

This study initiated with clinical history, general and oral examination after attaining a written informed consent from the patients. Further, provisional diagnosis, CBCT indication and treatment advised were noted. The CBCT imaging was done for the mandible bilaterally using CBCT machine CS-9600 with exposure parameter 90kV, 10mA and voxel size 300µm scan was taken with exposure time 20 seconds. The acquired image was captured by Dimax3 Ceph digital sensor and CS 3D imaging software was used (Image1,2,3). These digital images were then carefully evaluated on CS 3D imaging software by two experienced Oral Radiologist for radiographic evaluation of mental foramen in the jaw. The location of the mental foramen were analyzed and classified under the following position.

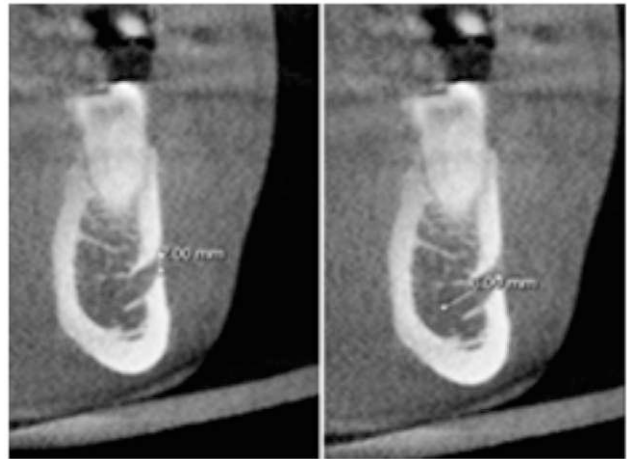


Image1: Height and length of mental foramen.

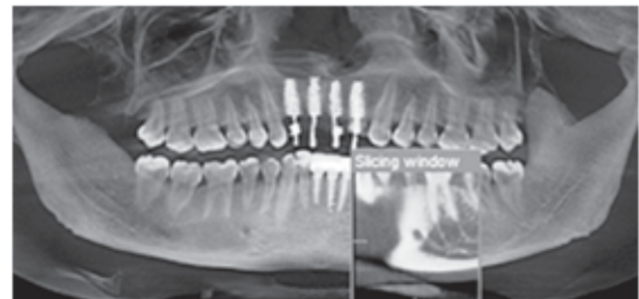

Image 2: Position of mental foramen.

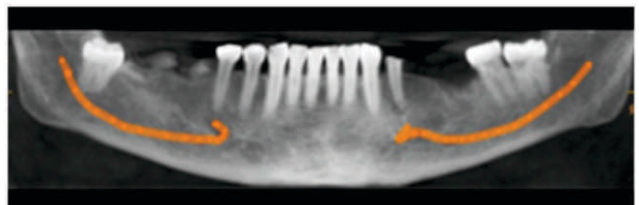


Image3: Anterior loop of inferior alveolar nerve canal.

- I- between canine and first premolar;
- II- below the first premolar;
- III- between first and second premolars;
- IV- below the second premolar;
- V- between second premolar and first molar;
- VI- below the first molar.^[3]

The data was tabulated and analyzed using SPSS software Version 25.0 (SPSS Inc., Chicago, IL, USA). Descriptive statistics and chi-square test were used to analyse the results and p-value of ≤ 0.05 was considered significant.

- I- between canine and first premolar;

- II- below the first premolar;
- III- between first and second premolars;
- IV- below the second premolar;
- V- between second premolar and first molar;
- VI- below the first molar.^[3]

RESULTS:

When we compare the frequency distribution of mental foramen size in the 200 patients in this study, the largest number of subjects (70.5%) exhibited large size mental foramens, while only 29.5% showed small size. Of all the males, 73% had large mental foramens and 27% had small ones, based on gender. The difference in the size of the mental foramen in 32.0% of females and 68.0% of females was not statistically significant. When the size of mental foramen was compared by side, 23.5% of large foramen and 9.5% of tiny foramen were found on the right side (Table 1, Figure 1). There were 20% small and 47% large foramens on the left side, with no discernible difference between the two sides (Table 2, Figure 2).

The frequency distribution of mental foramens according to position shows that there are 44.5% foramens between the first and second premolars and 55.5% below root apex of second premolar's apical root. The gender distribution of males and females indicates that more foramens were seen in the space between the second premolars' apical roots (57.0%, 54.0%). The difference between the first and second premolar positions was seen in 43.0% of males and 46.0% of females, although it was not statistically significant. Table 3, Figure 3 shows the distribution of foramen on the right and left sides in males between the first and second premolars: 44.2% are found on the right side and 55.8% are found on the left side, while in females, the distribution is 43.5% on the right side and 56.5% on the left side. At apical roots of 2nd premolar, in males 47.4% present at right and 52.6% present at left side. In females 48.1% present at right and 51.9% present at left side and the difference between the groups were also not statistically significant (Table 4, Figure 4).

Table 1: Frequency distribution of mental foramen according to size and gender (n-200).

Size of metal foramen	Male n (%)	Female n (%)	Total n (%)	Chi- square value	p-value
Big	73(73.0%)	68 (68.0%)	141 (70.5%)	0.601	0.535
Small	27 (27.0%)	32(32.0%)	59(29.5%)		
Total	100 (100%)	100(100%)	200 (100%)		

n- Number of samples

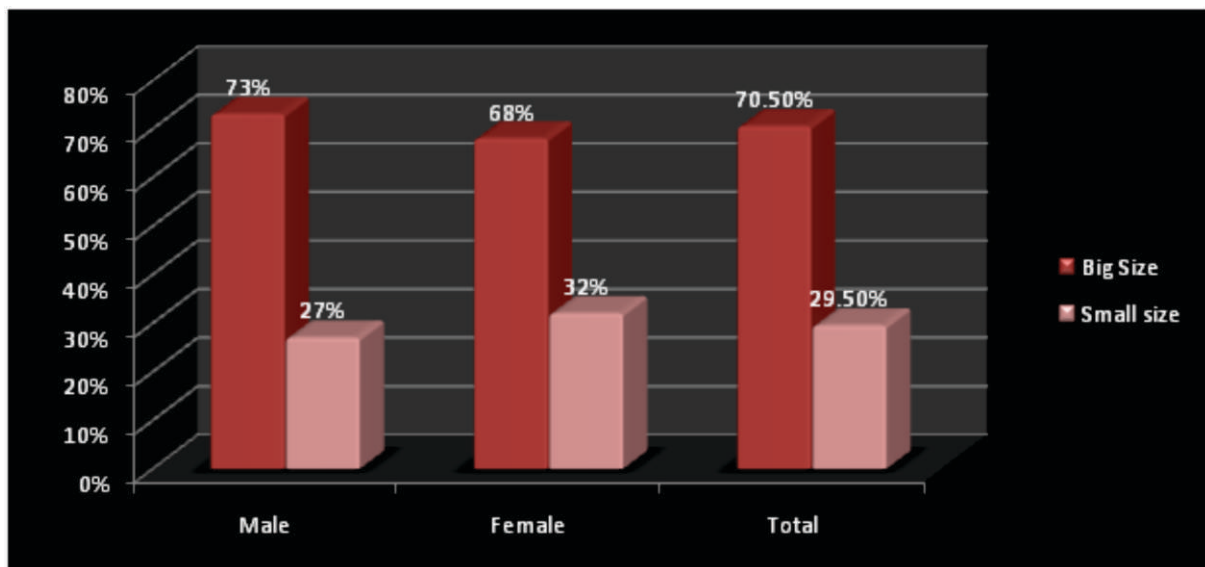


Figure 1: Frequency distribution of mental foramen according to size and gender.

Table 2: Frequency distribution of size of mental foramen according to right and left side and gender (n=200).

Side of mental foramen	size	Male n (%)	Female n (%)	Total n (%)	Chi-square value	p-value	
Right side	Big	24 (24.0%)	23(23.0%)	47 (23.5%)	0.644	0.886	
	Small	9(9.0%)	10(10%)	19 (9.5%)			
Left side	Big	49 (49.0%)	45(45.0%)	94(47.0%)			
	Small	18(18.0%)	22(22.0%)	40(20.0%)			
Total	100(100%)	100 (100%)	200 (100%)				

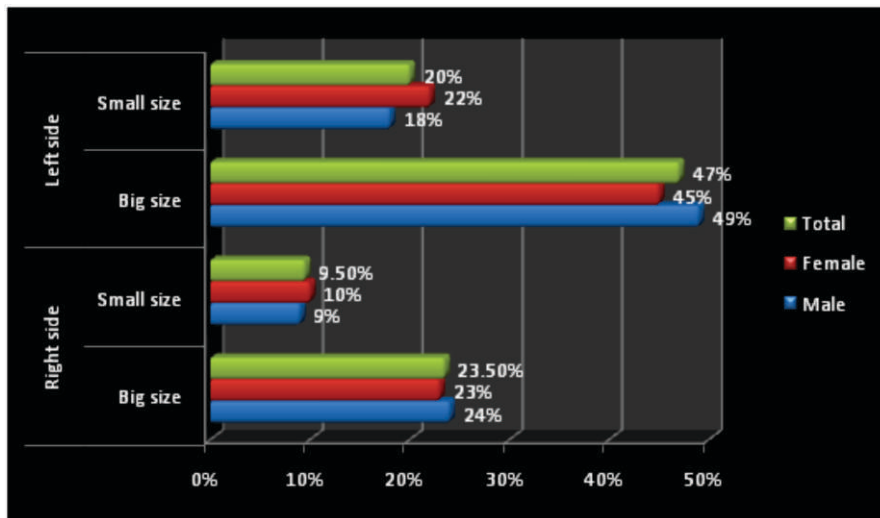


Figure 2: Frequency distribution of size of mental foramen according to right and left side and gender.

Table 3: Frequency distribution of mental foramen according to position in mandibular and gender (n=200).

Position of mental foramen	Male n (%)	Female n (%)	Total n (%)	Chi-square value	p-value
Between 1 st and 2 nd Premolar	43 (43.0%)	46 (46.0%)	89 (44.5%)	0.182	0.776
Root apex of 2 nd premolar	57 (57.0%)	54 (54.0%)	111(55.5%)		
Total	100 (100%)	100(100%)	200(100%)		

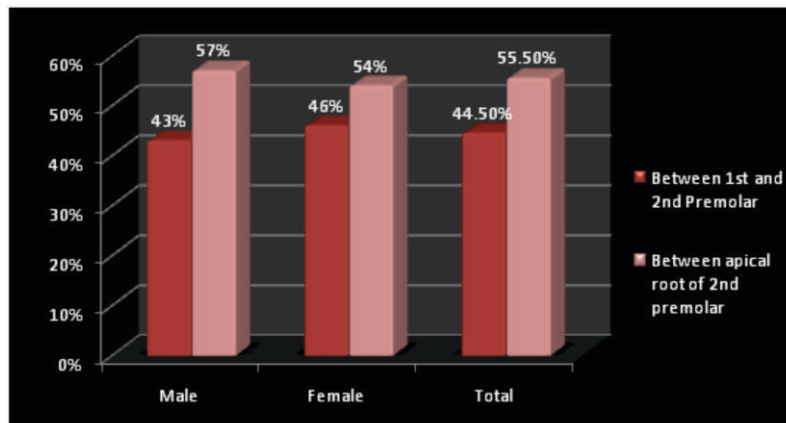
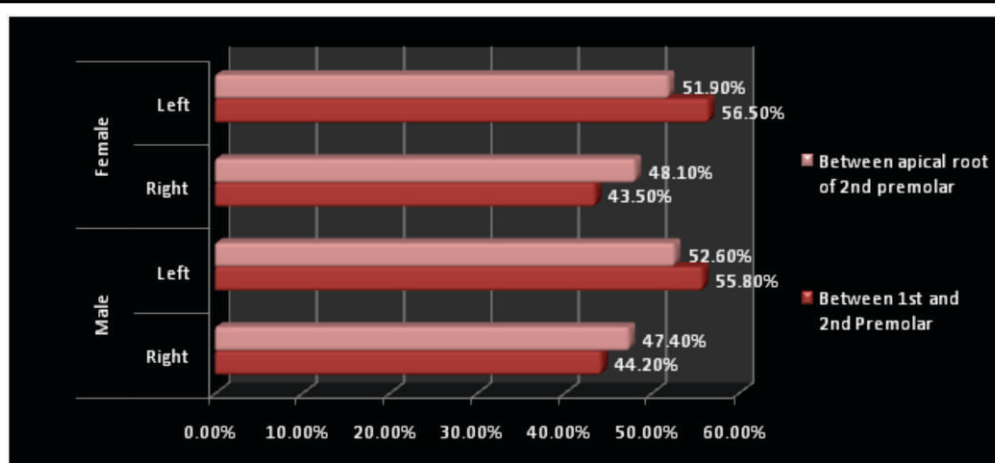


Figure 3: Frequency distribution of mental foramen according to position in mandibular and gender.

Table 4: Frequency distribution of mental foramen according to right and left position in mandibular and gender (n-200).

Gender	Side	Between 1 st and 2 nd Premolar n (%)	Root Apex of 2 nd premolar n (%)	Total n (%)	Chi-square value	p-value
Male	Right	19 (44.2%)	27(47.4%)	46(46.0%)	0.100	0.341
	Left	24(55.8%)	30(52.6%)	54(54.0%)		
	Total	43 (43.0%)	57 (57.0%)	100 (100%)		
Female	Right	20 (43.5%)	26(48.1%)	46 (46.0%)		
	Left	26 (56.5%)	28(51.9%)	54(54.0%)		
	Total	46 (46.0%)	54 (54.0%)	100 (100%)		
Total	89 (44.5%)	111(55.5%)	200(100%)			

**Figure 4:** Frequency distribution of mental foramen according to right and left position in mandibular and gender.

Only 19% of round foramen was found, however the majority (81.0%) of oval foramen were detected based on the shape of the mental foramen at the right side. Gender-wise, 75% of men and 87% of women had oval-shaped foramens, whereas 25% of men and 13% of women had round foramens. This difference was statistically significant ($p=0.031$). Likewise, on the left side, there was 74% oval and just 26% round foramen. The foramen shapes of 62% of males and 86% of females were oval, whereas 38% of males and 26.9% had round shapes, and the difference was statistically significant ($p=0.000$) (Table 5; Figure 5).

DISCUSSION:

The mental foramen is a strategically important landmark during surgical procedures. Its location, number of foramina, and possibility of anterior loop of the mental nerve or AMF (accessory mental foramen) being present need to be considered before surgery to avoid mental nerve injury. The damage to mental foramen or inferior alveolar nerve during oral surgery or implant placement is a serious complication.^[5]

Procedures such as placement of dental implants, osteotomy, bone harvesting, although considered to be safe elective procedures, sensory disturbances have been reported as a complication in upto 31% of patients in the first two weeks following surgery, with 10-15% of patients continuing to complain of sensory disturbances even up to 15 months after procedure.^[6] This radiographic study was aimed to evaluate the morphology and dimensions of mental foramen and the anterior loop with an objective to assess their variations among Indian population. This study also assessed the dimorphic variations of mental foramen and its anterior loop with respect to gender and laterality using CBCT.

In the present study the largest number of subjects (70.5%) exhibited large size mental foramens, while only 29.5% showed small size. Of all the males, 73% had large mental foramens and 27% had small ones. Whereas of all 68% female has larger mental foramen and 32% mental foramen are smaller in size. R. Dos Santos Oliveira, has found similar differences in the size of mental foramen in male and female where male exhibit large size of mental foramen then

Table 5: Frequency distribution of shape of mental foramen according to right and left position in mandibular and gender (n-200).

Side	Shape	Male	Female	Total	Chi- square value	p-value
Right side	Round	25 (25.0%)	13 (13.0%)	38 (19.0%)	4.678	0.031*
	Oval	75(75.0%)	87 (87.0%)	162 (81.0%)		
	Total	100 (100%)	100(100%)	200(100%)		
Left side	Round	38 (38.0%)	14(14.0%)	52(26.0%)	14.969	0.000*
	Oval	62(62.0%)	86(86.0%)	148(74.0%)		
	Total	100 (100%)	100 (100%)	200(100%)		

*Statistically Significant

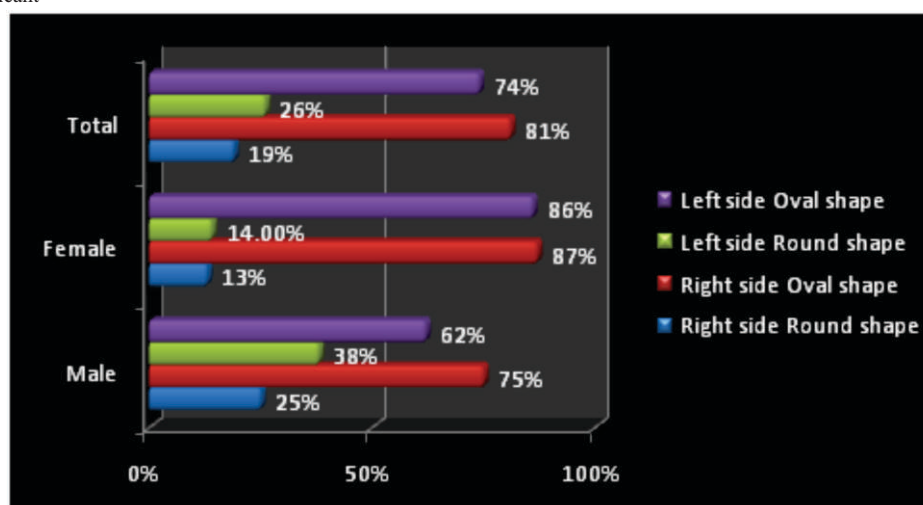


Figure 5: Frequency distribution of shape of mental foramen according to right and left position in mandibular and gender.

female.^[7] The results were consistent with those found by Gungor et al. , Zhang et al., and Kalender et al. , in which the horizontal and vertical diameters evaluated also in CBCT study were higher in men in comparison to women.^{[8],[9],[10]} In the present study when the size of mental foramen was compared by side, 23.5% of large foramen and 9.5% of tiny foramen were found on the right side. There were 20% small and 47% large foramens on the left side, with no discernible difference between the two sides.

In the present study 44.5% mental foramen were located in between the first and second premolars and 55.5% at the apex of second premolar's root. Similarly, P. Carruth et al. reported the gender distribution of male and female which indicates that more foramens were shown in the space between the second premolars' apical roots (57.0%, 54.0%).^[11] Whereas in Antoinette Pele et al. study, gender and side did not seem to have influence on the mental foramen location in relation to the teeth.^[12] According to Chen et al., the presence of an anterior loop of the inferior alveolar nerve (AL) could have an influence on the position of MF to the teeth. Indeed, at the majority

position, without AL, the MF was found at 51.7% between PM1 and PM2, whereas when there was an AL, it was found at 73.3% apically to the PM2.^[13] On the contrary, in Krishnan et al.'s study, no significant difference was noticed.^[14] The results of the present study corroborated the data from Indian populations reported by Bhagat et al.^[15] Alok et al.,^[16] Swamy et al.,^[17] and Srivastava et al.^[18] which conclusively stated that the most common position of MF in the Indian population was below the mandibular second premolar, followed by the position between the 2 premolars.

In present study the distribution of foramen on the right and left sides in males between the first and second premolars: 44.2% are found on the right side and 55.8% are found on the left side, while in females, the distribution is 43.5% on the right side and 56.5% on the left side. At the apex of roots of 2nd premolar, in males 47.4% present at right and 52.6% present at left side. In females 48.1% present at right and 51.9% present at left side and the difference between the groups were also not statistically significant. Similarly Komal Sheth et al. found mental foramens were most often located at the apex of the mandibular second

premolar.^[19] On both the left and right sides, both males and females predominantly showed the mental foramen in the second premolar region, followed by distal to the first premolar and medial to the second premolar. The root apex of the second premolar on both sides of the mandibular arch was closest to the mental foramen in the sagittal plane, which is in agreement with study performed by Phillips JL et al.^[20] and Ngeow WC^[21]

In the present study majority of the foramen was oval shaped on and only 19% were of round shape at the right side. Gender-wise, 75% of men and 87% of women had oval-shaped foramens, whereas 25% of men and 13% of women had round foramen.^{[19][20]} The results coincided with the left side as well as maximum number of foramen were oval shaped which was 74% oval and just 26% round foramen (Table5; Figure 5) Komal Sheth et al in her study showed that on the left side, 71% (337/475) of cases had the root apex of the second premolar closest to the mental foramen, whereas on the right side, 62% (295/475) of cases had the root apex of the second premolar closest to the mental foramen, which is similar to the pattern found on the contra lateral side.^{[19][20]} The next most frequent location of the mental foramen was between First Premolar and Second Premolar position, which was found in 14% (67/475) of cases on the left side and in 26% (124/475) of cases on the right side.

The inconsistent position of the mental foramen should always be considered while investigating radiographic periapical areas and while performing periodontal or endodontic surgery in the area between the canine and the mesial root of the first molar. Furthermore, the position of the mental foramen varies across ethnic groups,^[21] which should alert the clinician to consider variability in their patient populations.

The data was subjected to intra and inter examiner variability. Statistical analysis showed there was no significant difference in the intra as well as inters examiner observations. Ludlow JB et al. Found CBCT scans to have an error of less than 0.6% while measuring mandibular anatomy.^[22] This suggest that measurements made on CBCT images are accurate and reproducible. Thus, high resolution CBCT images are considered one of the most promising and precise techniques that accurately determine the mental foramen for varied applications in dentistry.

CONCLUSION:

The morphology of the mental foramen showed variations among the gender and age in Bhopal population. Hence, treatment planning that involves

the interforaminal region of the mandible should be carried out on a case-by-case basis to determine appropriate location and dimension of mental foramen. A good intra and inter examiner reliability was observed in our study, suggesting that measurements made on CBCT images are accurate and reproducible.

Financial Support and Sponsorship

Nil.

Conflicts of Interest

There are no conflicts of interest.

REFERENCES:

1. Agarwal DR, Gupta SB. Morphometric analysis of mental foramen in human mandibles of south Gujarat. *PJSR*. 2011;4:15-8. doi.org/10.5281/zenodo.8274219
2. Nimje DA, Wankhede HA, Hosmani PB. Morphometric study of the mental foramen in dry adult human mandibles. *Int J Recent Trends Sci Technol*. 2014;12: 47-9. doi.org/10.18535/jmscr/v6i4.136
3. Phillips JL, Weller RN, Kulild JC. The mental foramen: 1. Size, orientation, and positional relationship to the mandibular second premolar. *J Endod*. 1990 May;16(5):221-3. doi: 10.1016/s0099-2399(06)81674-2. PMID: 2074415.
4. Chakraborty R, Sen S, Panchbhai A, Bhowate RR, Dupare A. Comparison between conventional radiograph and 3D volumetric radiograph for determining the morphology and morphometry of mental foramen. *J Indian Acad Oral Med Radiol* 2019;31:17-23.
5. Juodzbalys G, Wang HL, Sabalys G. Injury of the Inferior Alveolar Nerve during Implant Placement: a Literature Review. *J Oral Maxillofac Res*. 2011 Apr 1;2(1):e1. doi: 10.5037/jomr.2011.2101. PMID: 24421983; PMCID: PMC3886063.
6. Ravindra S, Chandra P, Pachipulusu B, Morphology and morphometric analysis of mental foramen in south Indian population – A CBCT study. *IP Int J Maxillofac Imaging*. 2022;8:45-55. doi.org/10.18231/ j.ijmi. 2022. 012
7. Dos Santos Oliveira R, Rodrigues Coutinho M, Kühl Panzarella F. Morphometric Analysis of the Mental Foramen Using Cone-Beam Computed Tomography. *Int J Dent*. 2018 Mar 26;2018:4571895. doi: 10.1155/2018/4571895. PMID: 29785185; PMCID: PMC5892272.
8. Gungor E, Aglarci OS, Unal M, Dogan MS, Guven S. Evaluation of mental foramen location in the 10-70 years age range using cone-beam computed tomography. *Niger J Clin Pract*. 2017 Jan;20(1):88-92. doi: 10.4103/1119-3077.178915. PMID: 27958253.
9. Li Y, Yang X, Zhang B, Wei B, Gong Y. Detection and characterization of the accessory mental foramen using cone-beam computed tomography. *Acta Odontol Scand*.

- 2018 Mar;76(2):77-85. doi: 10.1080/00016357.2017.1382715. Epub 2017 Sep 28. PMID: 28956507.
10. Kalender A, Orhan K, Aksoy U. Evaluation of the mental foramen and accessory mental foramen in Turkish patients using cone-beam computed tomography images reconstructed from a volumetric rendering program. *Clin Anat*. 2012 Jul;25(5):584-92. doi: 10.1002/ca. 21277. Epub 2011 Oct 4. PMID: 21976294.
 11. Carruth P, He J, Benson BW, Schneiderman ED. Analysis of the Size and Position of the Mental Foramen Using the CS 9000 Cone-beam Computed Tomographic Unit. *J Endod*. 2015 Jul;41(7):1032-6. doi: 10.1016/j.joen.2015.02.025. Epub 2015 Apr 3. PMID: 25843751.
 12. Pelé A, Berry PA, Evanno C, Jordana F. Evaluation of Mental Foramen with Cone Beam Computed Tomography: A Systematic Review of Literature. *Radiol Res Pract*. 2021 Jan 6;2021:8897275. doi: 10.1155/2021/8897275. PMID: 33505723; PMCID: PMC7806401.
 13. Chen Z, Chen D, Tang L, Wang F. Relationship between the position of the mental foramen and the anterior loop of the inferior alveolar nerve as determined by cone beam computed tomography combined with mimics. *J Comput Assist Tomogr*. 2015 Jan-Feb;39(1):86-93. doi: 10.1097/RCT.000000000000166. PMID: 25299797.
 14. Thiruvenkata Krishnan D, Joylin K, I P, M K, Hearty Deepak J, Ilango S, Hamad KA, Shanab H, Salama MH, Jayakumar S. Assessment of the Anterior Loop and Pattern of Entry of Mental Nerve Into the Mental Foramen: A Radiographic Study of Panoramic Images. *Cureus*. 2024 Mar 5;16(3):e55600. doi: 10.7759/cureus.55600. PMID: 38586811; PMCID: PMC10995115.
 15. Bhagat J, Shah D, Fernandes G. Prevalence of the Mental Foramen Location in an Indian Subpopulation: A Retrospective Orthopantomogram Study. *International Journal of Oral Care and Research*, April-June 2018;6(2):89-92
 16. Alok, Abhijeet; Singh, Indra Deo; Panat, Sunil R; Singh, Shivani; Kishore, Mallika; Jha, Abhinav. Position and symmetry of mental foramen: A radiographic study in bareilly population. *Journal of Indian Academy of Oral Medicine and Radiology* 2017;29:16-19. DOI:10.4103/jiaomr.JIAOMR_69_16
 17. Nagaraj T. Radiographic study of mental foramen type and position in Bangalore population. *Journal of Medicine, Radiology, Pathology & Surgery*. 2015; doi: 10.15713/ins.jmrps.2
 18. Srivastava S, Sethi KK, Sinha A, Srivastava A, Mishra A, Khan N, Pandey S, Dixit A. Assessing the Prevalence and Length of the Anterior Loop of Inferior Alveolar Nerve and the Position and Dimension of Mental Foramen Using Cone Beam Computed Tomography. *Cureus*. 2024 Sep 3;16(9):e68535. doi: 10.7759/cureus.68535. PMID: 39233731; PMCID: PMC11373582.
 19. Sheth K, Banga KS, Pawar AM, Gutmann JL, Kim HC. Shape and anatomical relationship of the mental foramen to the mandibular premolars in an Indian sub-population: a retrospective CBCT analysis. *Restor Dent Endod*. 2021 Dec 13;47(1):e1. doi: 10.5395/rde.2022.47.e1. PMID: 35284321; PMCID: PMC8891471.
 20. Phillips JL, Weller RN, Kulild JC. The mental foramen: 1. Size, orientation, and positional relationship to the mandibular second premolar. *J Endod*. 1990 May;16(5):221-3. doi: 10.1016/s0099-2399(06)81674-2. PMID: 2074415.
 21. Ngeow WC, Yuzawati Y. The location of the mental foramen in a selected Malay population. *J Oral Sci*. 2003 Sep;45(3):171-5. doi: 10.2334/josnusd.45.171. PMID: 14650583.
 22. Ludlow JB, Laster WS, See M, Bailey LJ, Hershey HG. Accuracy of measurements of mandibular anatomy in cone beam computed tomography images. *Oral Surg Oral Med Oral Pathol Oral Radiol Endod*. 2007 Apr;103(4):534-42. doi: 10.1016/j.tripleo.2006.04.008. Epub 2006 Aug 4. PMID: 17395068; PMCID: PMC3644804.